

The Use of Non-invasive Pulsed Acoustic Cellular Expression System to Promote Angiogenesis in Chronic Wounds

Dr. Windy Cole, DPM

Adjunct Professor and Director of Wound Care Research, College of Podiatric Medicine, Kent State University

Introduction

Chronic lower extremity wounds present significant challenges with regard to effective wound management. Ischemia, microcirculatory dysfunction and PVD cause limitations in blood flow that can delay the healing process.

An innovative, non-invasive pulsed acoustic cellular expression (PACE) system delivers high-energy acoustic pressure waves using the electrohydraulic shockwave principle to produce compressive and tensile stresses on cells and tissue in order to promote angiogenic and positive inflammatory responses.

There are various methods for measuring skin perfusion and wound tissue oxygenation. One such device is a novel near-infrared spectroscopy (NIRS) device that captures the percentage of oxygenated hemoglobin in and around the wound.

Background

This is a prospective, single site, single-arm pilot case series. The goal of this study aims to determine the effects of weekly PACE therapy on localized skin perfusion and wound healing as measured with a near-infrared imaging device.

Methods

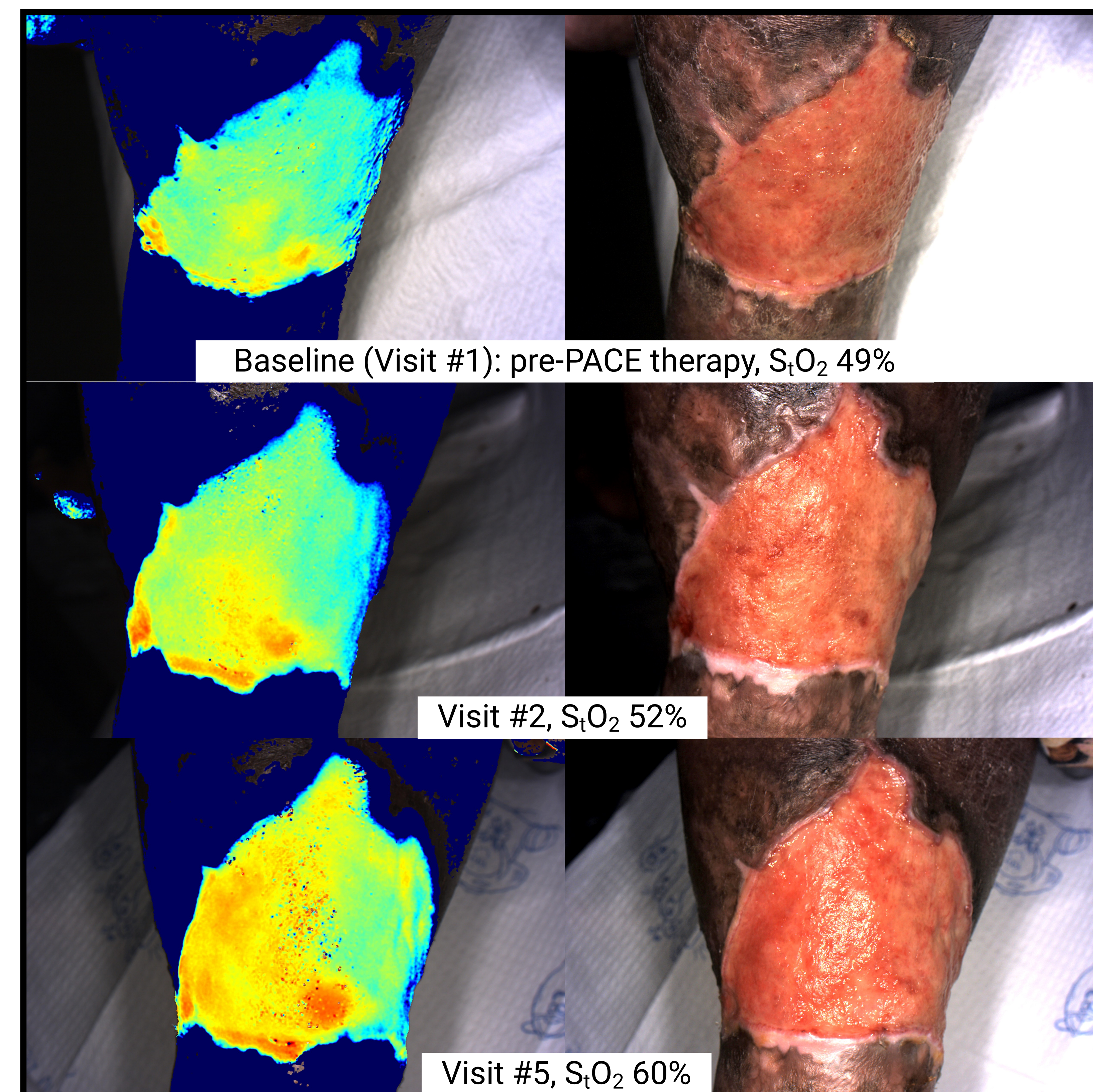
Eight (8) patients with a history of diabetes and lower extremity wounds were treated with the PACE system according to wound size, after signing the informed consent form. A baseline standard image with initial wound measurements and NIRS image was taken prior to starting the PACE therapy. Subsequent weekly NIRS images of the wounds were taken prior to the PACE treatment. Changes in amounts of oxygenated hemoglobin in the wound, as well as wound measurements, were also measured weekly. Patients were seen for 5 visits and had a total of 4 PACE treatments each, unless the wound healed.

Results

In the 8 patients receiving PACE therapy, all displayed an increase in oxygenated hemoglobin in the wound base as demonstrated on the NIRS images. All 8 patients showed development of more granulation tissue in the wound bed utilizing the PACE system. Weekly wound measurements were also improved in this patient cohort.

Conclusion

In the author's opinion PACE therapy offers an improved non-invasive standard of care that may initiate the healing cascade and shorten wound healing by improving microcirculation and oxygenated hemoglobin, subsequently allowing for the regeneration of tissue such as granulation tissue and skin in chronic wounds. The NIRS device proved to be a very user-friendly point-of-care imaging device to track weekly wound progress.



	Description	Initial	Final	Change
Patient 1	Wound Size	9.5 cm x 9.8 cm x 0.1 cm	8.7 cm x 9.5cm x 0.1 cm	-1.05 cm ³
	S _t O ₂	49%	60%	11%
Patient 2	Wound Size	9.5 cm x 7.8 cm x 1.0 cm	9.0 cm x 7.1 cm x 0.6 cm	-35.76 cm ³
	S _t O ₂	57%	62%	5%
Patient 3	Wound Size	1.2 cm x 1.3 cm x 0.1 cm	Wound Healed	-0.16 cm ³
	S _t O ₂	58%	71%	13%
Patient 4	Wound Size	11.1 cm x 2.2 cm x 0.3 cm	8.9 cm x 1.7 cm x 0.3 cm	-5.81 cm ³
	S _t O ₂	80%	83%	3%
Patient 5	Wound Size	9.3 cm x 7.6 cm x 0.1 cm	9.0 cm x 6.9 cm x 0.1 cm	-0.86 cm ³
	S _t O ₂	57%	72%	15%
Patient 6	Wound Size	1.7 cm x 1.0 cm x 0.1 cm	Wound Healed	-0.17 cm ³
	S _t O ₂	69%	77%	8%
Patient 7	Wound Size	5.0 cm x 1.5 cm x 0.1 cm	Wound Healed	-0.75 cm ³
	S _t O ₂	69%	71%	2%
Patient 8	Wound Size	0.8 cm x 0.7 cm x 0.1 cm	Wound Healed	-0.06 cm ³
	S _t O ₂	82%	85%	3%

Table 1. Wound size and tissue oxygenation measurement at start and completion of PACE therapy.

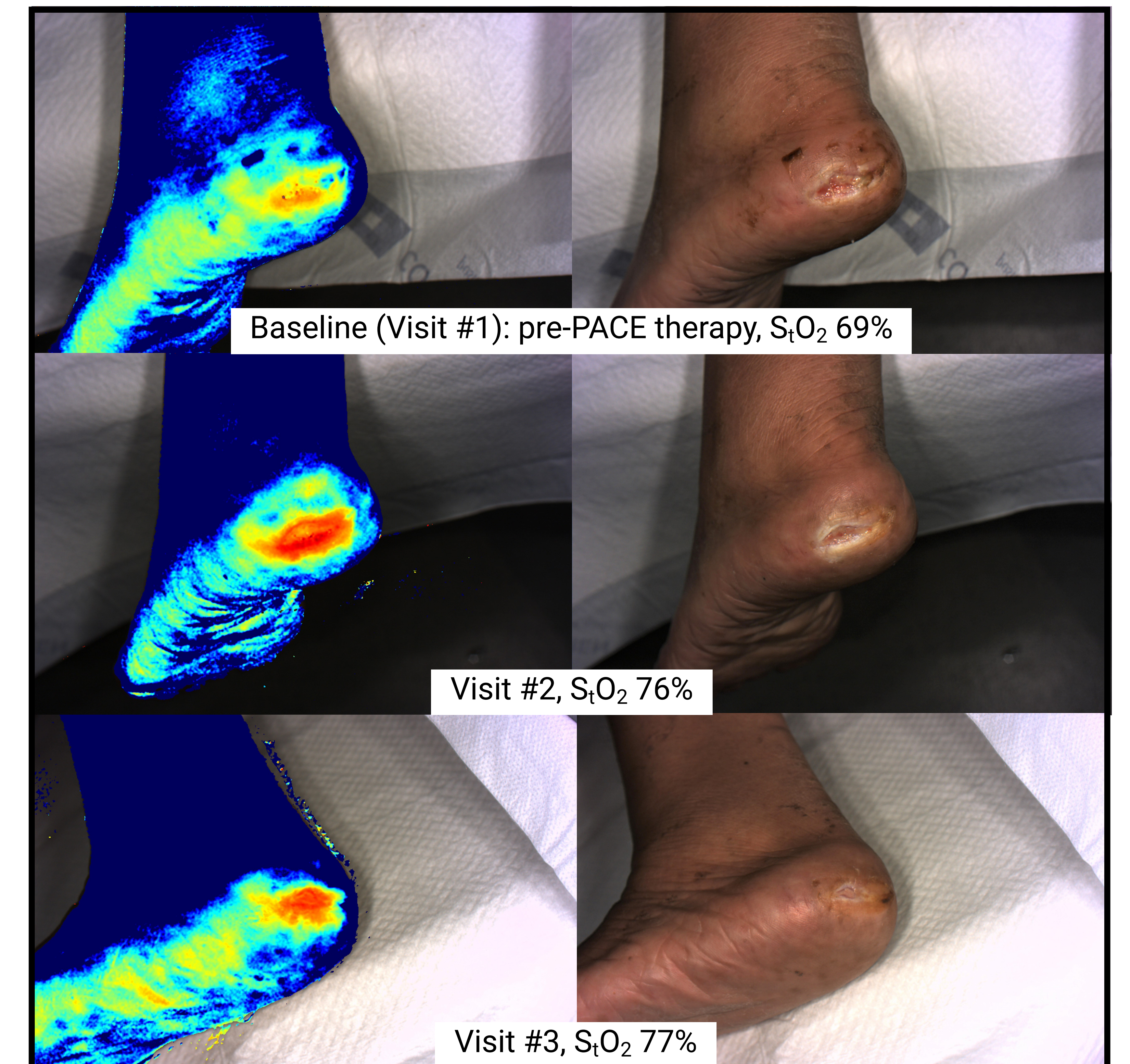


Figure 2. Patient 6 visual series (NIRS/Clinical images). Wound healed after three PACE therapy treatments.